

The Occurrence and Morphology of a Lateral Metatarsal Splint Bone in Moose (*Alces alces*)

WILLIAM J. SILVIA,^{1*} ROLF O. PETERSON,² WILLIAM F. SILVIA,¹
JOHN A. VUCETICH,² AND ALEXANDER W. SILVIA¹

¹Department of Animal and Food Sciences, University of Kentucky, Lexington, Kentucky

²School of Forest Resources and Environmental Science, Michigan Technological University, Houghton, Michigan

ABSTRACT

Moose (*Alces alces*) appear to be different from most other cervids in that a well-developed metatarsal splint bone is present. It is found apposed to the plantolateral portion of the cannon bone in over 70 % of adults. It averages 3.3 mm in width and extends about 22% of the total length of the metatarsal. It may be derived through calcification of connective tissue or by elongation of the vestigial metatarsal V. *Anat Rec*, 294:231–235, 2011. © 2010 Wiley-Liss, Inc.

Key words: moose; metatarsal

Moose (*Alces alces*) are members of the family Cervidae (deer). The phylogenetic relationships within the Cervidae have been the subject of extensive review (Groves and Grubb, 1987; Gilbert et al., 2006). Cervids are pecoran artiodactyls in which metapoidals III and IV are fused to form a single bone, commonly referred to as the “cannon” bone. Metapoidal I is consistently absent. The abaxial metapoidals, II and V, are significantly reduced on both the thoracic and pelvic limbs. The major classification within the Cervidae is based on accessory metacarpal morphology (Brooke, 1878). In telemetacarpal cervids [ex. Roe deer (*Capreolus capreolus*), white-tailed deer (*Odocoileus virginianus*)] the distal portion of the regressed metacarpals 2 and 5 remain while in plesiometacarpal cervids [ex. wapiti (*Cervus elaphus*), Fallow deer (*Dama dama*)] the proximal portion is retained. This morphologically based, phylogenetic grouping has been substantiated by more recent molecular (Randi et al., 1998; Hassanin and Douzery, 2003; Fernandez and Vrba, 2005; Gilbert et al., 2006) and behavior-based comparisons (Cap et al., 2002). Moose are telemetacarpal cervids (Bubenik, 1998).

In contrast to the metacarpals, the accessory metatarsals in most cervids have regressed to such an extent that they are not mentioned in descriptions of their skeletal anatomy (Groves and Grubb, 1987; Bubenik, 1998). We have observed that moose are somewhat different from other cervids in that a robust lateral metatarsal splint bone is frequently present. In this report, we describe the presence and morphology of this splint bone

in a very isolated and well-studied population of moose from Isle Royale National Park, MI.

MATERIALS AND METHODS

Descriptive observations and quantitative measurements of metatarsal morphology of North American moose (*Alces alces*) were made on 531 metatarsals collected from Isle Royale National Park, MI (Peterson, 1977). All specimens were obtained from animals that died of natural causes. Age was determined by counting the number of layers in the cementum of teeth (Sergeant and Pimlott, 1959; Wolfe, 1969). Sex was determined based on the presence (males) or absence (females) of antler pedicels. The presence or absence of the metatarsal splint bone was recorded. The qualitative description of the splint bone included a description of the proximal and distal ends. Each end was classified as fused to the cannon bone (distinct end not discernable) or distinct (distinct end discernable). If distinct, the end was present in two forms. It could be apposed to the cannon bone

*Correspondence to: William J. Silvia, Department of Animal and Food Science, 409 WP Garrigus Bldg, University of Kentucky, Lexington, KY 40546-0215. Tel.: 859-257-7545, Fax: 859-257-7537. E-mail: wsilvia@uky.edu

Received 14 June 2010; Accepted 4 October 2010

DOI 10.1002/ar.21323

Published online 22 December 2010 in Wiley Online Library (wileyonlinelibrary.com).

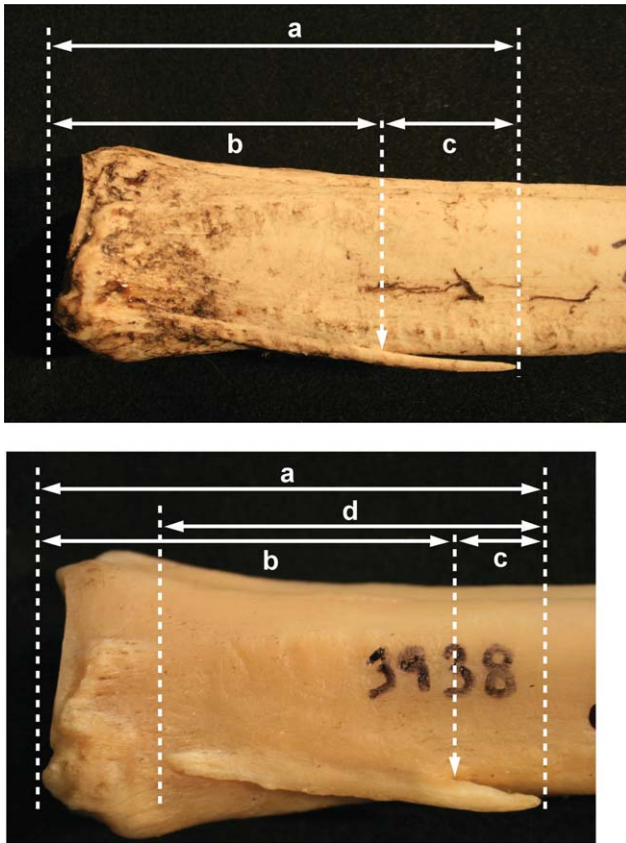

Fig. 1. Lateral view of the proximal end of the cannon bone showing typical examples of lateral metatarsal splint bone structure at the proximal end. In the upper panel, the proximal end of the splint bone fuses with the cannon bone and is indistinguishable. Measurements taken on this form of the splint bone are indicated: (a) distal extension of the splint bone, (b) distal extension of the apposed portion of the splint bone, and (c) length of the free distal portion of the splint bone. In the lower panel, a distinct proximal end is clearly discernable. Measurements taken on this form of the splint bone are indicated: (a) distal extension of the splint bone, (b) distal extension of the apposed portion of the splint bone, and (c) length of the free distal portion of the splint bone, (d) length of the splint bone.

over its whole length or a portion could be separate from the cannon bone. If distinct and separate, the end was subclassified as either intact or broken. Examples of the fused and distinct conditions are shown in Fig. 1. Quantitative measurements on the length of the splint bone could be made on specimens in which the distal end was distinct. For specimens in which the proximal end was fused, the distal extension of the apposed portion was measured from the most proximal extension in the plantolateral quadrant of the proximal articular surface. In specimens where the distal end was not broken, the total distal extension of the splint bone could be measured from the proximal articular surface as described above. It was also possible to measure the length of the free portion of the distal end. The dimensions measured are depicted in Fig. 1 (top panel). The same dimensions were measured in specimens with a distinct proximal end. In addition, it was possible to obtain the measurement of the length of the splint bone, from the proximal

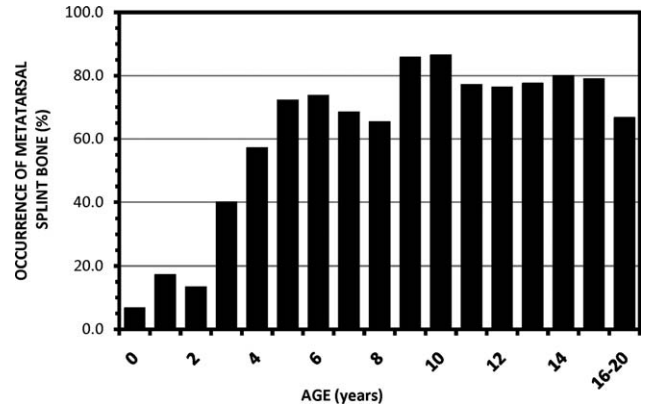


Fig. 2. Effect of age on percent of animals with a lateral metatarsal splint bone. The splint bone becomes more common as animals increase in age from birth to 5-year old ($P < 0.01$).

end to the distal end. These dimensions are depicted in Fig. 1 (bottom panel). The maximum width of the splint bone was measured for all configurations. There were 15 specimens that were fused at both ends, making measurements of lengths impossible. There were no specimens that were distinct at the proximal end and fused at the distal end.

Statistical Analyses

The distribution of qualitative characteristics (presence or absence of the metatarsal splint bone, classification of the ends of the splint bone as fused or distinct) and the effects of age or sex on that distribution were determined by chi-square (χ^2) analyses (SAS, 1985). The effects of age and sex on quantitative measurements (lengths and width of the metatarsal splint bone) were determined by analysis of variance using the general linear models (GLM) procedure of SAS (1985).

RESULTS

The percentage of specimens in which a metatarsal splint bone was observed varied with age ($P < 0.001$, Fig. 2). Less than 20% of the 0-, 1-, or 2-year old animals had a detectable splint bone. The percentage increased gradually as animals progressed from 2 through 5 years of age. By age 5, a splint bone was routinely observed in over 70% of the specimens. The percentage remained at this level for all older ages. The presence of the splint bone was not influenced by the sex of the animal at any age ($P = 0.28$). The proximal end of the splint bone was fused to the cannon bone in 81.5% of the specimens. A distinct, identifiable end was observed in just 18.5% of the specimens. The opposite was true at the distal end. There, 94.7% of the specimens had a distinct distal end. The distal end was fused with the cannon bone in just 5.3% of the specimens. The morphology of the proximal end (distinct vs. fused) had no relationship to the morphology of the distal end (Table 1). Thus, the most common configuration was for the proximal end of the splint bone to be fused to the cannon bone and for the distal end of the splint bone to be distinct. The next most common configuration was for both ends of the splint bone

to be distinct. None of the specimens that we examined were distinct at the proximal end and fused at the distal end. The distribution of splint bone morphologies was not different between males and females. The dimensions of the splint bone are summarized in Table 2. There was considerable variation in all aspects of the length of splint bone and this is reflected in the ranges reported. In the majority of specimens with a distinct distal end, the free distal portion of the splint bone was broken ($n = 193$ of 266, 73%). Measurements of the width and of the distal extension of the apposed portion of the splint bone could be made in most of the specimens ($n = 245$), regardless of the condition of the distal end. The distal extension of the apposed portion averaged 65.7 ± 0.9 mm. The width of the splint bone was 3.3 ± 0.05 mm. Measurements of distal extension and length of the free distal end could only be made in specimens in which the distal end was not broken. The distal end of the splint bone extended to 85.3 ± 2.3 mm from the proximal end of the cannon bone. This is about 22% of the total length of the cannon bone. The length of the free distal portion of the splint bone was 18.3 ± 1.6 mm. The length of the splint bone could only be determined in specimens in which the proximal end was distinct (not fused to the cannon bone) and the distal end was distinct and not broken ($n = 16$). In these specimens, the length of the splint bone was 48.0 ± 3.4 . The dimensions of the splint bone increased with age (Fig. 3). The distal extension of the splint bone and of the apposed portion reached the maximum length at 3–4 years of age. The width of the splint bone did not reach its maximum until 5–6 years of age. The effect of age on the length of the distal free portion of the splint bone was not significant due to the limited number of specimens measured and the enormous variation. The distal free portion was very short in specimens from animals less than 3 years of age. Due to limited numbers, it was not possible to determine an effect of age on the length of the splint bone in specimens with a distinct proximal end. In gen-

eral, the average dimensions of the splint bone were not different between specimens with fused versus distinct proximal ends. The only exception was that the distal extension of the apposed portion was longer in specimens in which the proximal end was distinct than in those in which the proximal end was fused ($P < 0.01$). In general, there were no differences in the dimensions of the splint bone between sexes (Table 3). The only exception was the width. The splint bone was slightly wider in males than in females ($P = 0.03$).

DISCUSSION

A distinct metatarsal splint bone is clearly present in the majority of specimens from adult moose collected from Isle Royale National Park. It is a long bone, relatively uniform in width throughout its length. It is tightly apposed to the lateral surface of the cannon bone, close to the edge formed where the lateral and plantar surfaces of the cannon bone meet. In most specimens, the longitudinal axis of the splint bone runs approximately parallel to the longitudinal axis of the cannon bone. There are some specimens in which the longitudinal axis of the splint bone runs at a distinctly different angle from that of the cannon bone. In more than 75% of the specimens, the proximal end of the splint bone blends smoothly into the lateral surface of the cannon bone such that a distinct proximal end cannot be identified. In contrast, the distal end in most specimens is distinct and a free portion, separate from the cannon bone, is present. The splint bone is slightly wider in males than females.

In mature moose (5-year old and older), the metatarsal splint bone is present in over 70% of the specimens. This percentage should be regarded as a preliminary estimate. At the time these specimens were collected, observation of the splint bone was not a consideration. It is possible that the splint bone is not always tightly apposed to the cannon bone. In these cases, it could be easily separated during postmortem degradation or specimen preparation. A shallow depression along the lateral side of the cannon bone where a splint bone could have been was observed in some specimens. The splint bone is not commonly found in specimens from animals less than 3-year old. This strongly suggests that it develops postnatally. It may be cartilaginous in young animals then calcifies around the time of epiphyseal plate closure, 2.5–4 years of age (Peterson, 1977). The splint bone does not articulate with either the cuboid or any of the other distal tarsal bones or with the proximal phalanx from digit 5.

TABLE 1. Relative distribution of end morphology of the lateral metatarsal splint bone (distinct vs. fused) in specimens from moose of all ages ($n = 281$)

		Distal end		
		Distinct	Fused	Totals
Proximal end	Distinct	52 (18.5%)	0 (0%)	52 (18.5%)
	Fused	214 (76.2%)	15 (5.3%)	229 (81.5%)
	Totals	266 (94.7%)	15 (5.3%)	281

TABLE 2. Dimensions of the lateral metatarsal splint bone in mature moose (age 5 years old or older). Numbers presented are mean \pm sem. All measurements are in mm. The range of observations is in parentheses after the mean

	All specimens	Distal end distinct and intact		
		Proximal end fused	Proximal end distinct	Both conformations
n	245	47	16	63
Extension	—	84.1 ± 2.6 (59–140)	88.9 ± 4.7 (54–130)	85.3 ± 2.3 (54–140)
Length	—	—	48.0 ± 3.4 (23–88)	—
Extension of apposed portion	65.7 ± 0.9 (30–111)	65.3 ± 1.8 (44–111)	72.0 ± 3.4 (49–100)	67.0 ± 1.6 (44–111)
Length of free distal portion	—	18.8 ± 2.0 (0–73)	16.9 ± 2.1 (3–30)	18.3 ± 1.6 (0–73)
Width	3.3 ± 0.05 (1–5)	3.5 ± 0.1 (2–5)	3.5 ± 0.1 (3–4)	3.5 ± 0.1 (2–5)

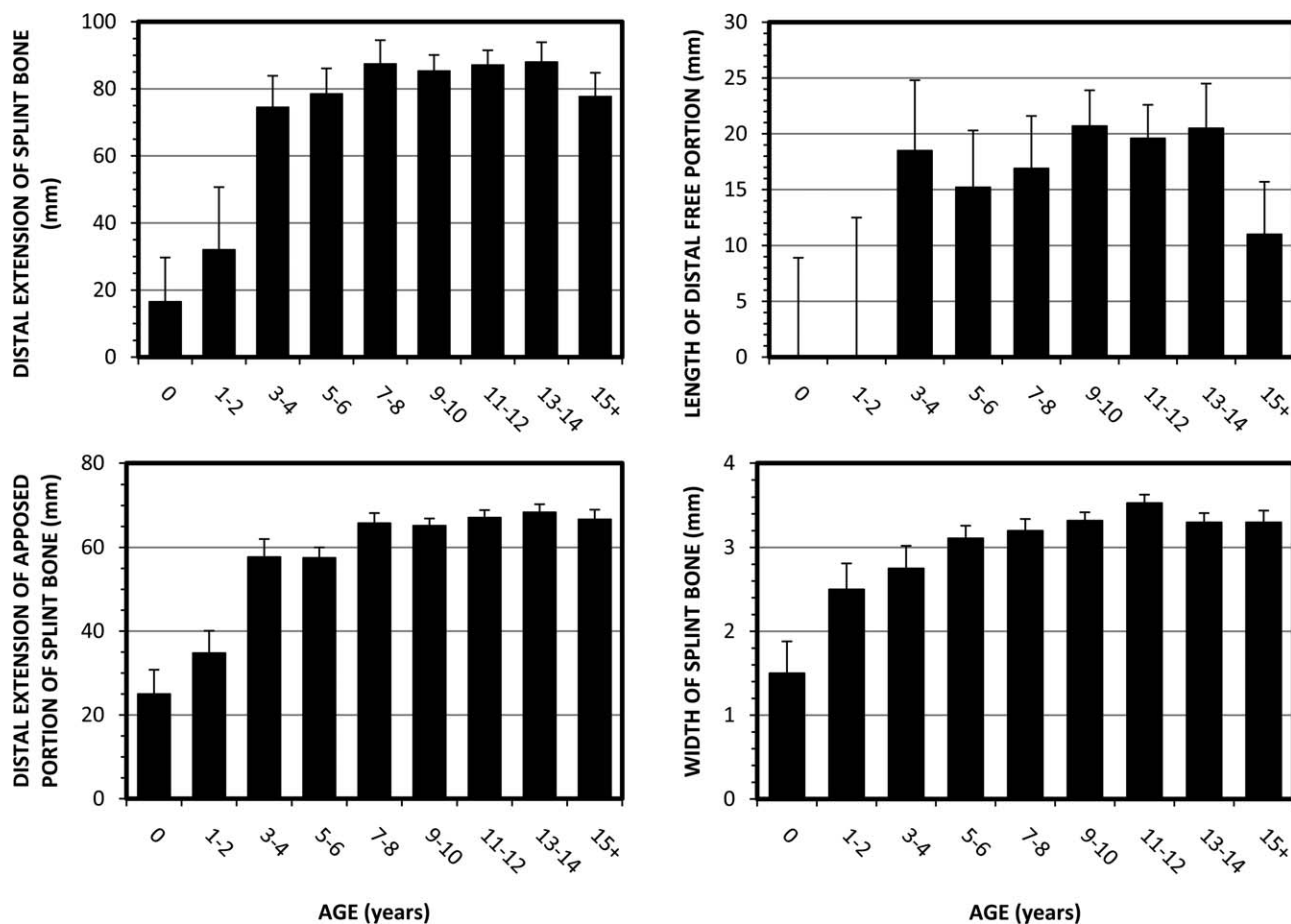


Fig. 3. Effect of age on the dimensions of the lateral metatarsal splint bone.

TABLE 3. Effect of sex on dimensions of the metatarsal splint bone in mature moose (age 5 years old or older). Numbers presented are mean \pm sem. All measurements are in mm. Number of observations are in parentheses after the mean

	Males	Females	Effect of sex (<i>P</i>)
Extension	88.1 \pm 3.2 (31)	82.6 \pm 3.2 (32)	0.234
Length	45.8 \pm 8.3 (4)	48.8 \pm 4.8 (12)	0.761
Extension of apposed portion	65.1 \pm 1.2 (125)	66.2 \pm 1.2 (119)	0.519
Length of free distal portion	20.9 \pm 2.2 (31)	15.8 \pm 2.2 (32)	0.110
Width	3.43 \pm .07 (123)	3.22 \pm .07 (120)	0.031

We can only speculate on the origin of the splint bone at this time. The metatarsal splint bone in moose is different from the paired telemetacarpal splint bones in its thoracic limb, in number, position and structure. The metacarpal splint bones are distally placed and articulate with the proximal phalanges of the dewclaws. The proximal position of the metatarsal splint bone in moose is somewhat similar to the plesiometacarpal splint bones in plesiometacarpal cervids, to the regressed metacarpal V in cattle and to the metapodial splint bones in horses (Sisson and Grossman, 1953). In these cases, the splint bone retains a well developed articular surface to one of the distal carpal bones and/or the adjacent metapodial IV. This surface is similar to that observed in less

derived artiodactyls that retain a complete metatarsal V such as the pig (Sack et al., 1982). In this respect, these examples are easily recognizable as "regressed" metapodials. In contrast, the metatarsal splint bone of the moose has a simple, flattened rod-like structure with no points of articulation at either end.

The metatarsal splint bone in moose may be the result of ossification of a tendon or ligament. In preliminary examination of the soft tissue anatomy of the hind limb in moose, we have found that the major tendons that control flexion and extension of the tarsal joint and phalanges pass over the dorsal and plantar surfaces of the cannon bone, as in other artiodactyls (Sisson and Grossman, 1953). However, there is a very fine ligament that runs

along the plantolateral edge of the cannon bone, from the distal end of the splint bone to a very small calcified terminus, near the proximal end of the first phalanx of the lateral dewclaw. To our knowledge, this ligament has not been described in other artiodactyls (Sisson and Grossman, 1953; Dyce et al., 2002). The splint bone may result from the calcification of the proximal end of this ligament.

It also seems possible that the metatarsal splint bone in moose may be derived through secondary growth of the vestigial metatarsal V, present in smaller cervids ancestral to the moose. If so, this may be an example of evolutionary "reversal" as defined by Hall (2003). The embryological development of metatarsal V has not been studied in moose. In cattle (*Bos taurus*), Hirt (1969) observed partially ossified metatarsal V on day 58 of gestation. Abaxial metapoidals were clearly present on day 73. By day 92 of gestation, "The fifth metacarpal and fifth metatarsal are reduced to tiny spurs..." Metatarsal V is not mentioned in the description of specimens from older fetuses. We can only assume that it is small enough to forego description. Peterson (1974) reported that the cannon bone has a high rate of growth in utero and is the "most developed" hind limb bone at birth in moose. It seems possible that rapid elongation of the cannon bone in moose could begin before the complete regression of metatarsal V. Secondary growth of metatarsal V may be stimulated by soluble growth factors elaborated by cellular elements in the epiphyses of the adjacent, rapidly elongating cannon bone. The ossified connection between the splint bone and the cannon bone may be the result of ossification of the interosseous ligaments that connect adjacent metatarsals. This occurs commonly in horses (Sisson and Grossman, 1953; Bendrey, 2007).

While generally not described, a form of metatarsal splint bone appears to be quite common in other cervids. In preliminary examination, it can be found in both white-tailed deer and wapiti (Silvia and Silvia, unpublished observations), telemetacarpal and plesiometacarpal species, respectively. In both of these species, the splint bone is observed less frequently and, when present, is much smaller than in moose. A comprehensive examination of other cervids is currently underway. From an evolutionary perspective, we have observed metatarsal splint bones of similar size and shape along the lateral side of cannon bones from *Cervalces scotti*, a large cervid, sister taxon to North American moose (Silvia, unpublished observations). A comprehensive evaluation of cannon bones from extinct members of the genera *Alces* and *Cervalces* as well as other, less-derived telemetacarpal cervids (ex. Roe deer), would be very beneficial in tracing the evolutionary development of this unusual splint bone conformation.

ACKNOWLEDGEMENTS

The authors thank all of the field workers who have collected metatarsal specimens on Isle Royale and contributed to the collection at Michigan Technological University. They are indebted to the officials with the United States Department of the Interior, National

Parks Service, and Isle Royale National Park for granting access to the park and permitting collection of these specimens. They also thank Christine Janis (Brown University) for helpful comments in the preparation of this manuscript. The authors also thank Mr. Mark Shermer for providing moose metatarsals upon which the first observations of the lateral splint bone were made. They appreciate the craftsmanship of Mr. Paul Poore for the modification of the vernier calipers used to measure the length of the cannon bone. The comments of the two anonymous reviewers were extremely helpful. This research was supported in part by the Kentucky Agricultural Experiment Station and is published with the approval of the director (publication number 10-07-083).

LITERATURE CITED

- Bendrey R. 2007. Ossification of the interosseous ligaments between the metapoidals in horses: a new recording methodology and preliminary study. *Int J Osteoarchaeology* 17:207–213.
- Brooke V. 1878. On the classification of the Cervidae, with a synopsis of the existing species. *Proc Zool Soc London* 1878:883–928.
- Bubenik AB. 1998. Evolution, taxonomy and morphophysiology. In: Franzmann AW, Shwartz CC, editors. *Ecology and management of North American moose*. Washington DC: Smithsonian Institution Press. p 77–123.
- Cap H, Aulagnier S, Deleporte P. 2002. The phylogeny and behavior of Cervidae (*Ruminantia Pecora*). *Ethol Ecol Evol* 14:199–216.
- Dyce KM, Sack WO, Wensing CJG. 2002. *Textbook of Veterinary Anatomy*. 3rd ed. Philadelphia: WB Saunders Co.
- Fernandez MH, Vrba E. 2005. A complete estimate of phylogenetic relationships in Ruminantia: a dated species-level supertree of the extant ruminants. *Biol Rev* 80:269–302.
- Gilbert C, Ropiquet A, Hassanin A. 2006. Mitochondrial and nuclear phylogenies of Cervidae (Mammalia, Ruminantia): systematics, morphology and biogeography. *Mol Phylogenet Evol* 40:101–117.
- Groves CP, Grubb P. 1987. Relationships of living deer. In: Wemmer CM, editor. *Biology and Management of Deer: Research Symposia of the National Zoological Park*. Washington DC: Smithsonian Institution Press. p 21–59.
- Hall BK. 2003. Descent with modification: the unity underlying homology and homoplasy as seen through an analysis of development and evolution. *Biol Rev* 78:409–433.
- Hassanin A, Douzery EJP. 2003. Molecular phylogeny of Ruminantia and the alternative position of Moschidae. *Syst Biol* 52:206–228.
- Hirt BJ. 1969. Development of the bovine appendicular skeleton. Dissertation (Ph.D.), Kansas State University.
- Peterson RO. 1974. Wolf ecology and prey relationships on Isle Royale. Thesis (Ph.D.), Purdue University.
- Peterson RO. 1977. Wolf ecology and prey relationships on Isle Royale. U.S. National Park Service Scientific Monograph Series 11. Washington DC: U.S. Government Printing Office.
- Randi E, Mucci N, Pierpaoli M, Douzery EJP. 1998. New phylogenetic perspectives on the Cervidae (Artiodactyla) are provided by the mitochondrial cytochrome b gene. *Proc R Soc Lond* 265:793–801.
- Sack WO, Hamilton WP, Horowitz A, Kramer B. 1982. *Pig Anatomy and Atlas*. Ithaca: Veterinary Textbooks Inc.
- SAS User's Guide: Statistics. 1985. Cary, NC: SAS Institute Inc.
- Sergeant DE, Pimlott DH. 1959. Age determination in moose from sectioned incisor teeth. *J Wildl Manage* 23:315–321.
- Sisson S, Grossman JD. 1953. *The Anatomy of the Domestic Animals*. 4th ed. Philadelphia: WB Saunders Co.
- Wolfe ML. 1969. Age determination in moose from cementum layers of molar teeth. *J Wildl Manage* 33:428–431.